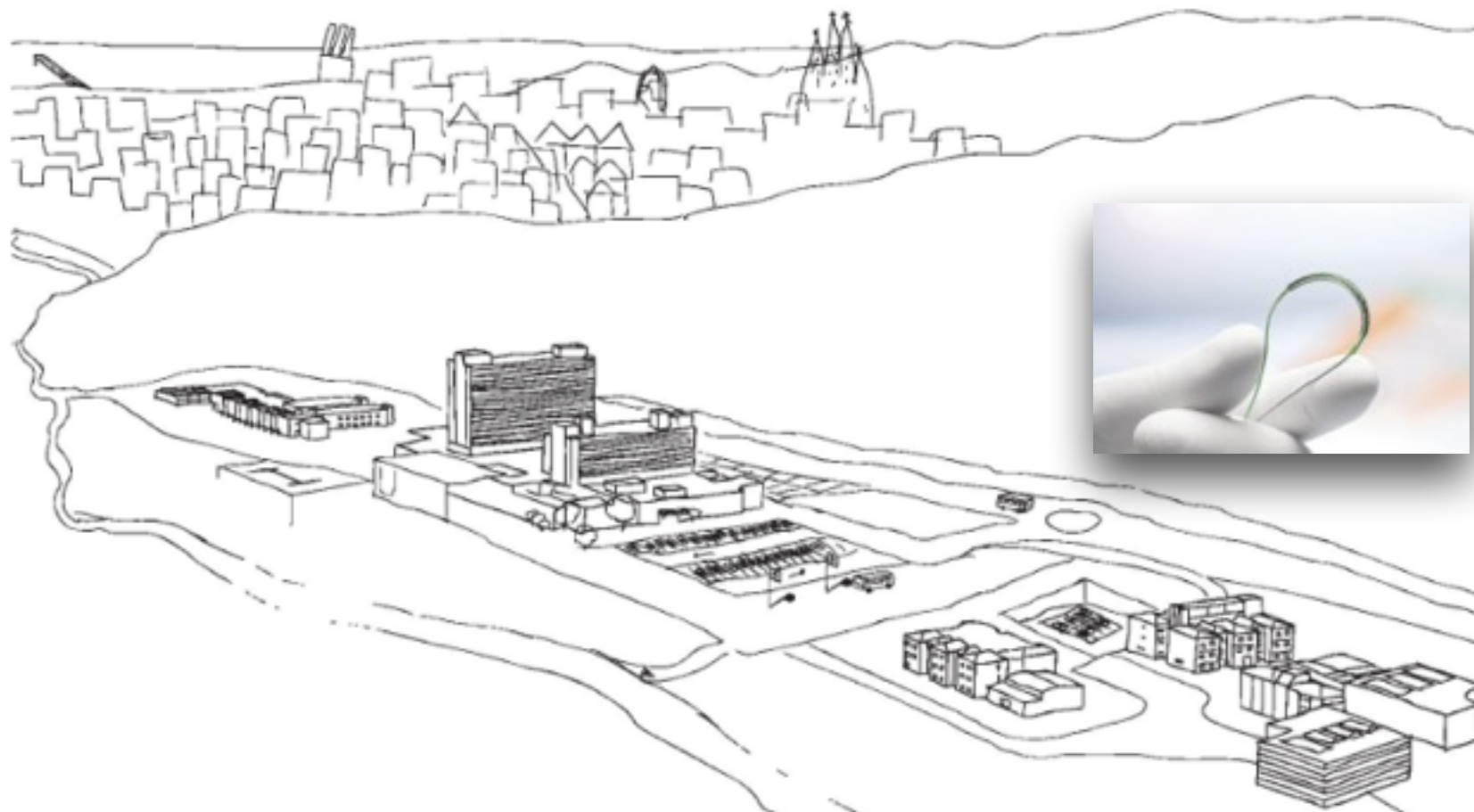



Germans Trias i Pujol
Hospital
Institut Català de la Salut

Institut Català de la Salut



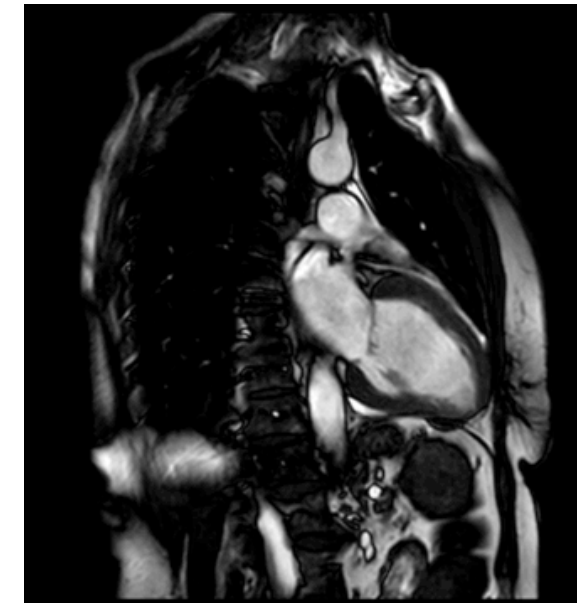
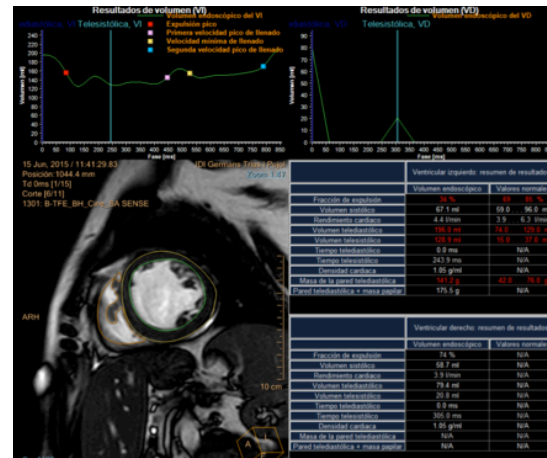
iCor.cat



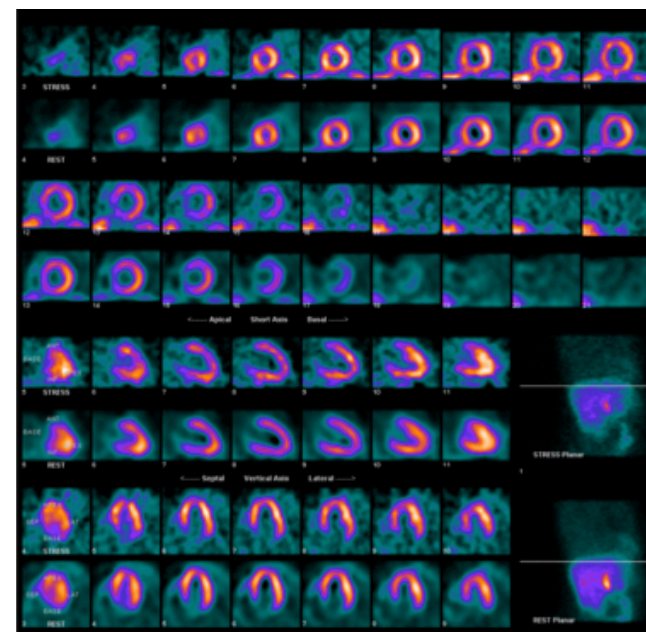
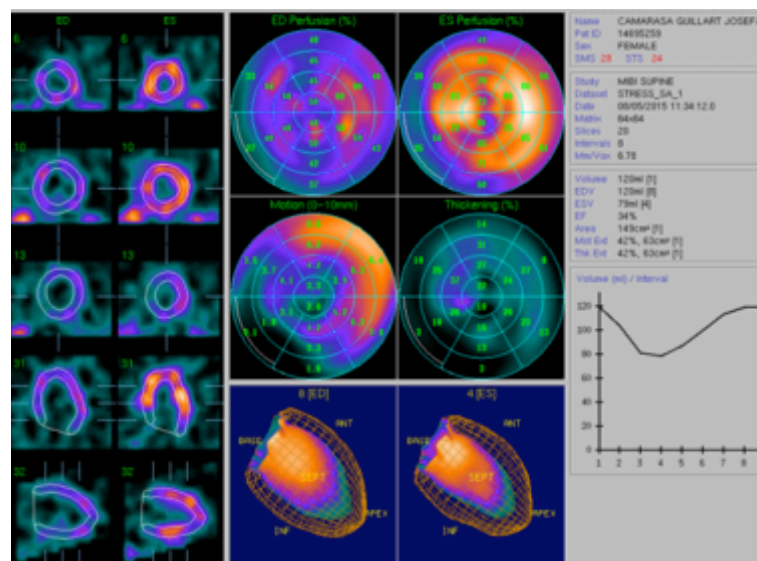
iCor.cat

Caso Clínico

- ♀ 76 a. HTA
- 2014 edemas. Eco FE 67%
- 2015 ICCV. Eco VI dilatado. FE 24%. proBNP ↑↑↑
- RNM no necrosis, no edema



- SPECT isquemia anteroapical e inferoseptal



Coronariografia

